The painful red eye

Dr. S. Gichuhi

RSVP

- **R**edness
- **S**ensitivity to light
- **V**isual loss
- **P**ain

Forms of conjunctival injection.

Conjunctival

Conjunctival disorders; conjunctivitis

Mixed

Corneal disorders with intraocular irritation; corneal ulcerations

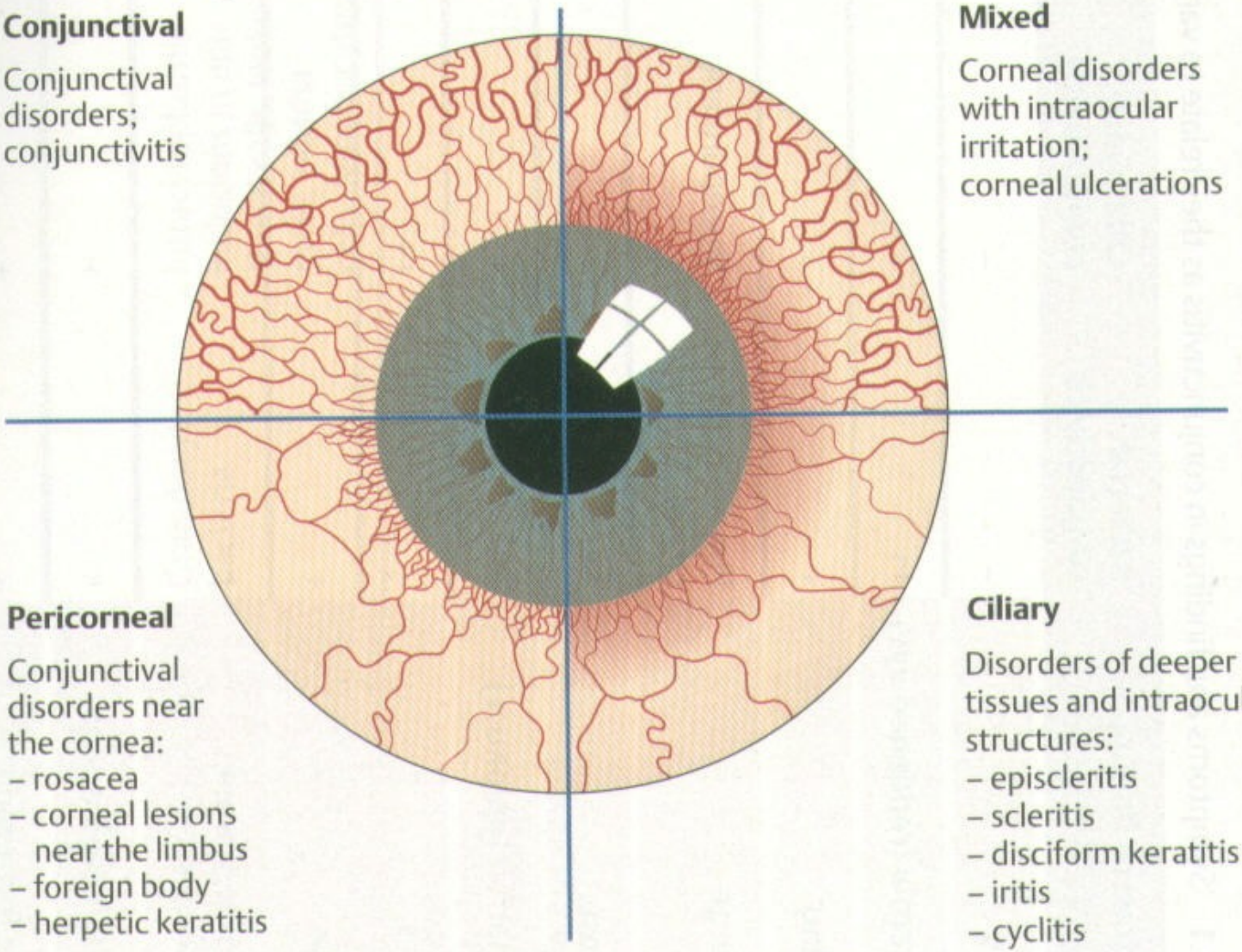

Pericorneal

Conjunctival disorders near the cornea:
- rosacea
- corneal lesions near the limbus
- foreign body
- herpetic keratitis

Ciliary

Disorders of deeper tissues and intraocular structures:
- episcleritis
- scleritis
- disciform keratitis
- iritis
- cyclitis

Fig. 4.6

Causes of moderate-severe pain

1. Cornea
   - ulcer
   - foreign body
   - abrasion
   - erosion
2. Anterior uveitis
3. Scleritis/ Episcleritis
4. Acute angle-closure glaucoma

Mild-moderate pain

1. Conjunctivitis
2. Inflammed pterygium/ pingueculum
3. Blepharitis
4. Stye
5. Superficial punctate keratitis (SPK)
6. Herpes simplex
7. Herpes zoster ophthalmicus

ulcer

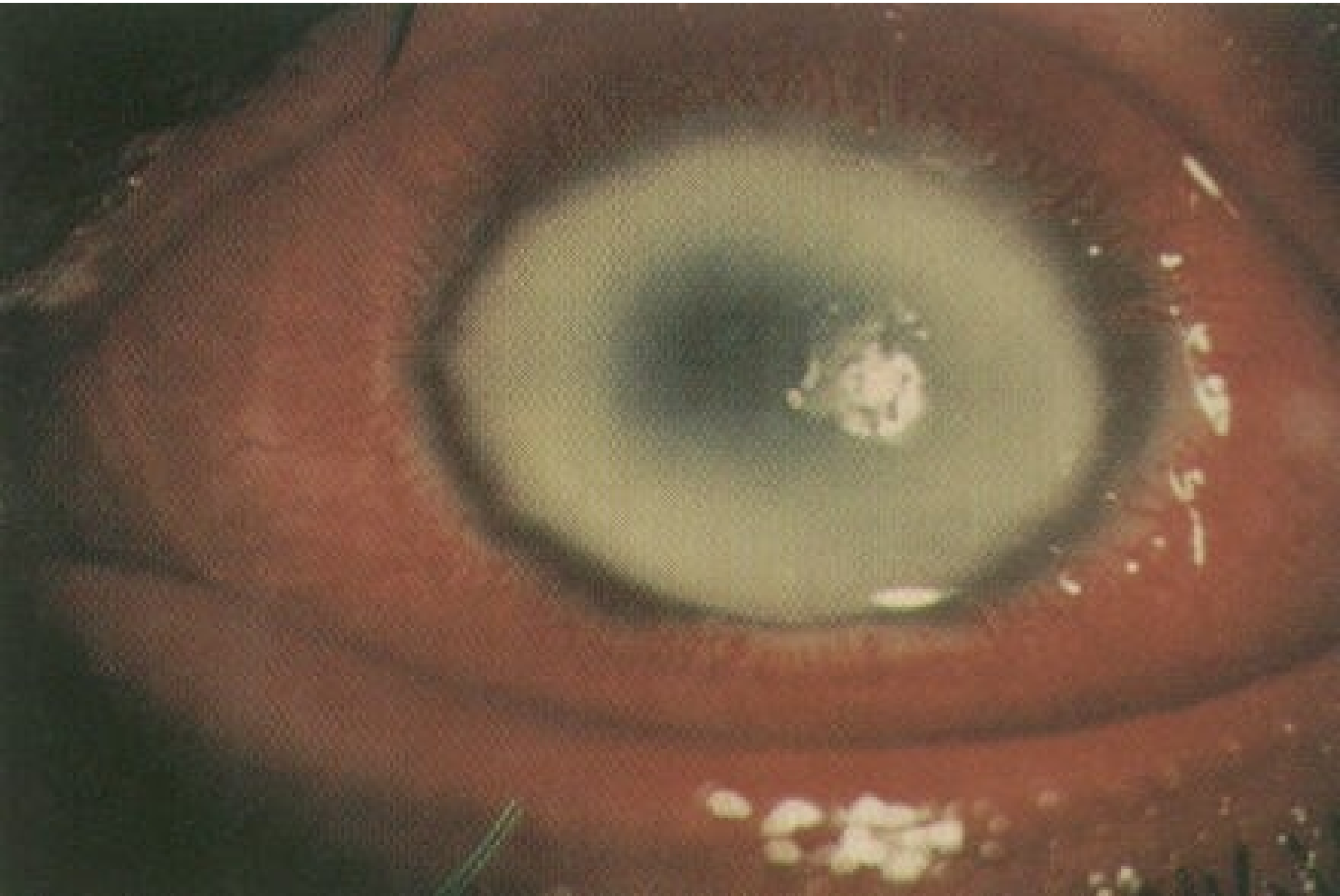

Predisposing factors for corneal ulcers

- Contiguous infection (blepharitis, dacryocystitis)
- Changes in corneal epithelium (dry eyes, Vitamin A deficiency)
- Contact lenses
- Lagophthalmos
- Neuroparalytic disorders
- Trauma
- Topical and systemic immunosuppresive agents

Conjunctival foreign body

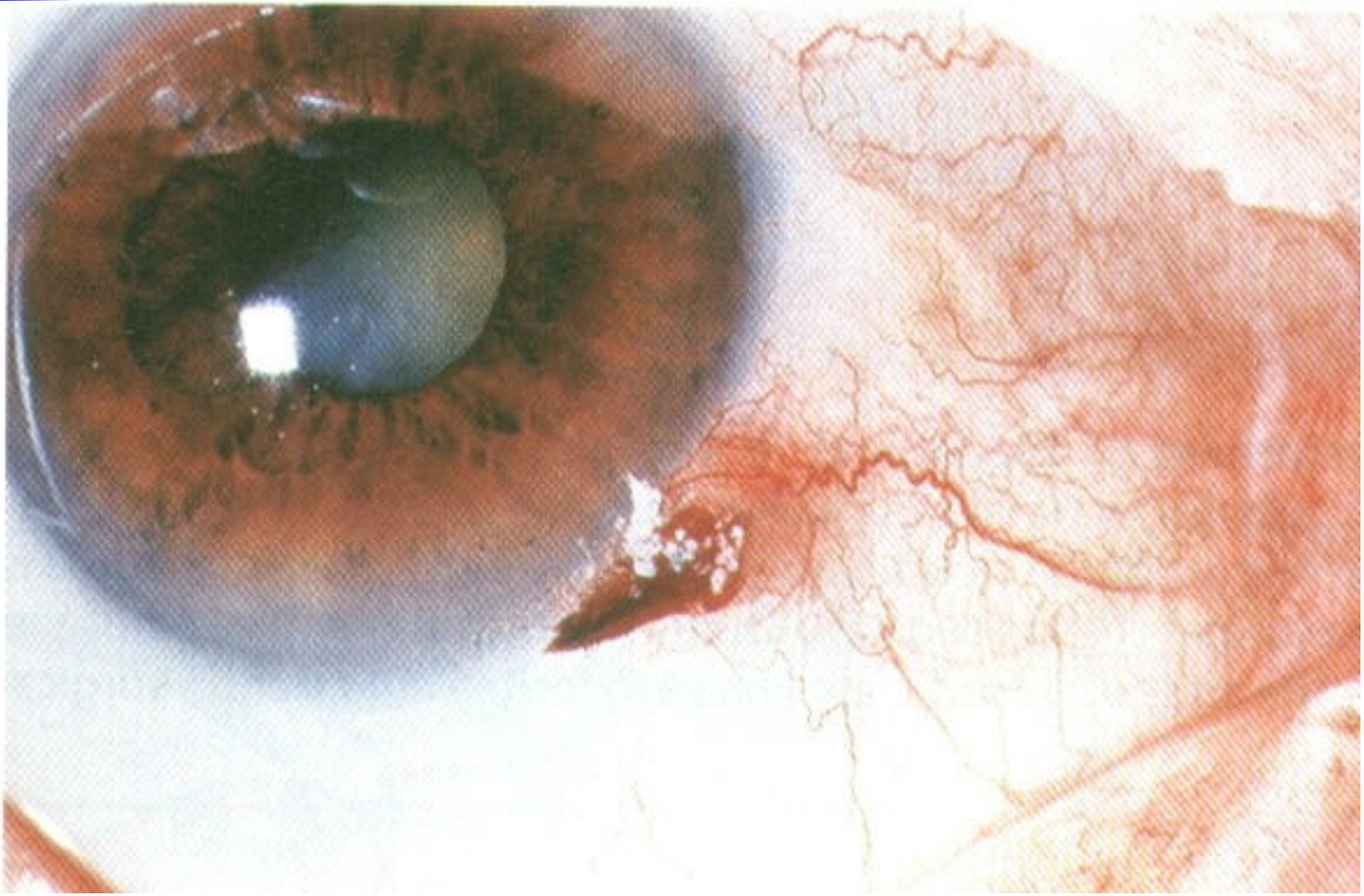

Corneal foreign body

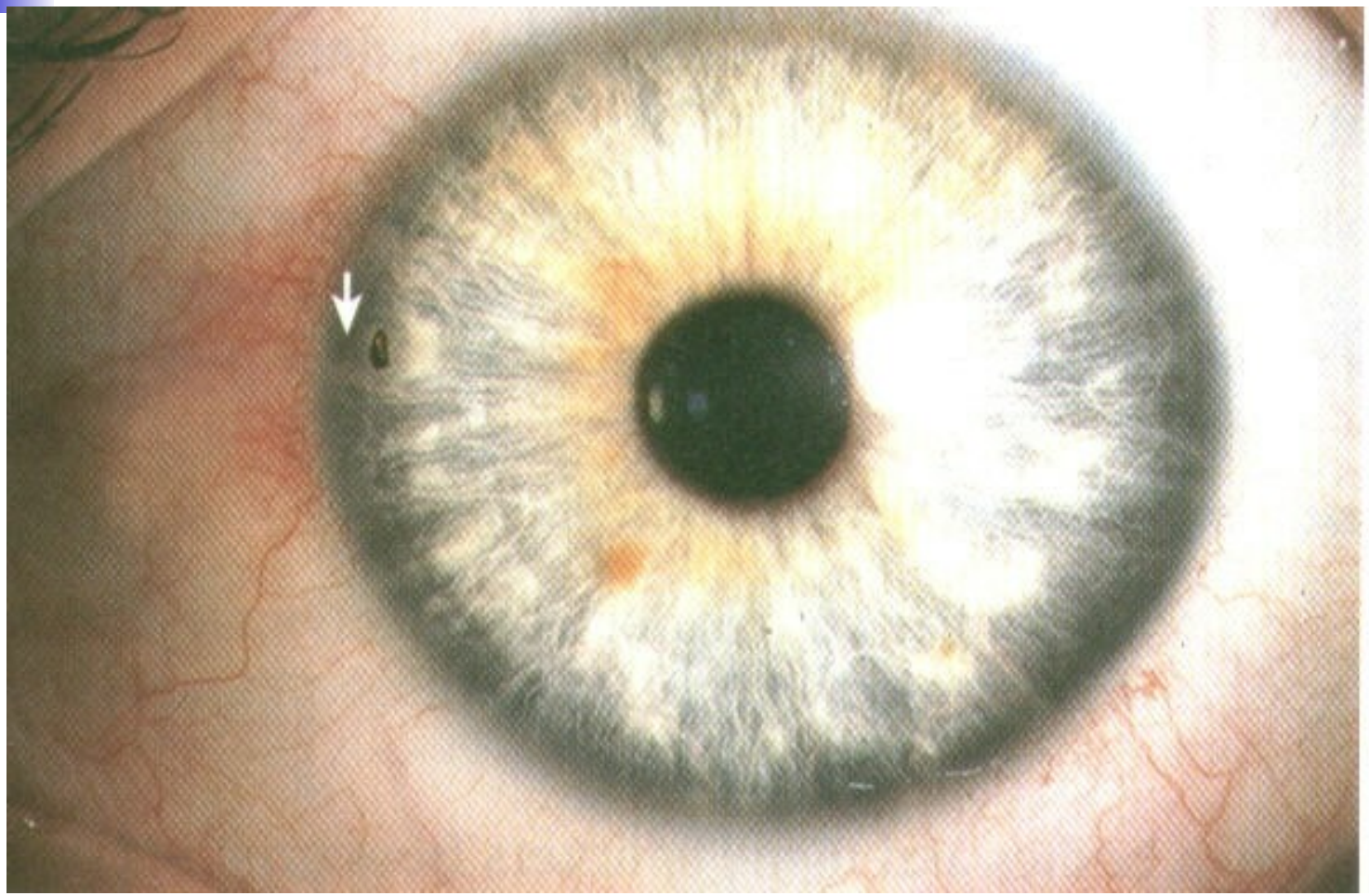

Anterior uveitis

- Iritis is the most frequent form
- Aetiology - mostly unknown
- Symptoms – RSVP, excessive tearing,OU
- Signs – ciliary injection, miosis, cells and protein in the AC
- Differential diagnosis – acute glaucoma
- Treatment – steroids, cycloplegia,
- Prognosis – usually improves in a few days

Complications of uveitis

Posterior synechiae - 30%

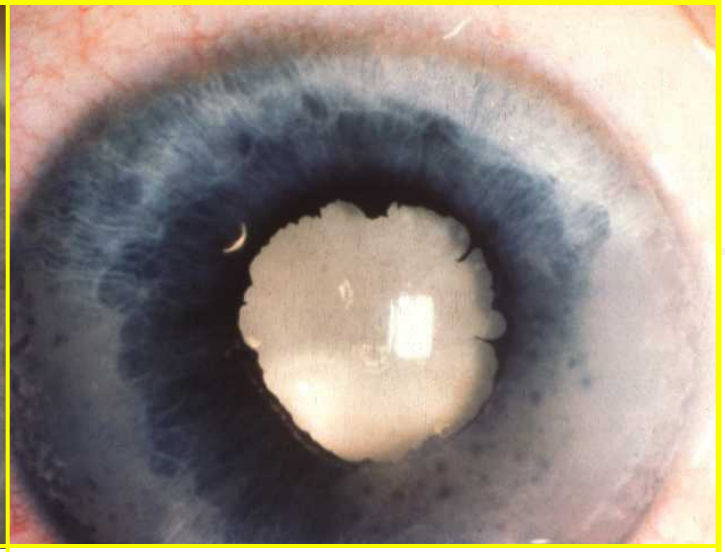

Cataract -20%

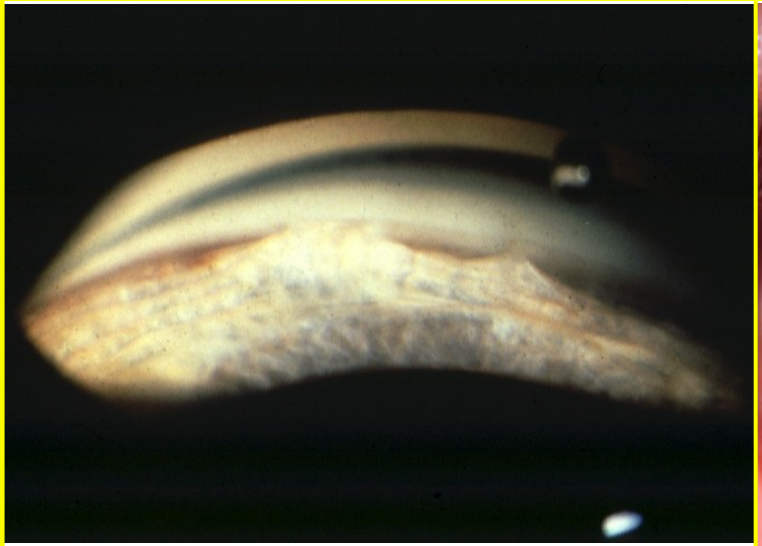

Glaucoma due to PAS - 15%

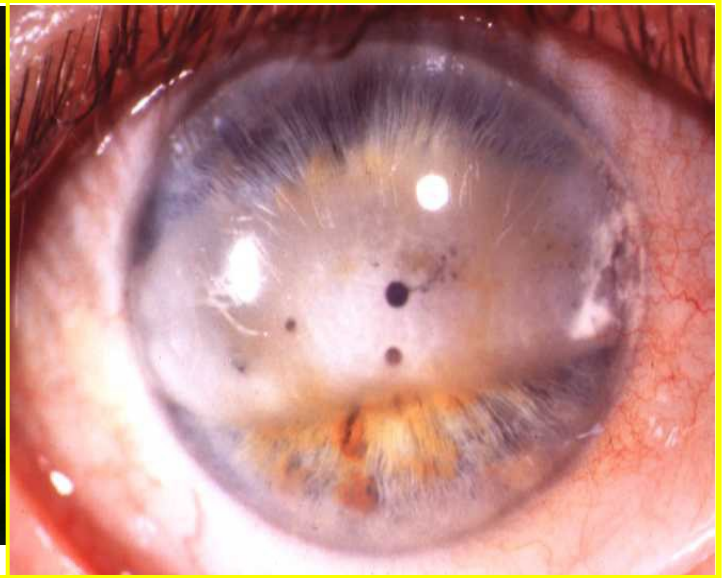

Band keratopathy - 10%

EPISCLERITIS AND SCLERITIS

1. Episcleritis

- Simple
- Nodular

2. Anterior scleritis

- Non-necrotizing diffuse
- Non-necrotizing nodular
- Necrotizing with inflammation
- Necrotizing without inflammation (scleromalacia perforans)

3. Posterior scleritis

Simple episcleritis

- Common, benign, self-limiting but frequently recurrent
- Typically affects young adults
- Seldom associated with a systemic disorder

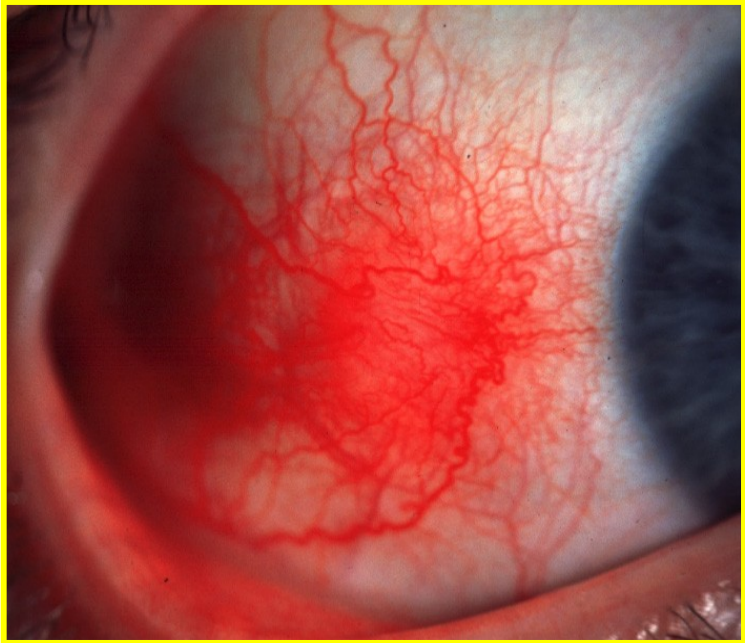

Simple sectorial episcleritis

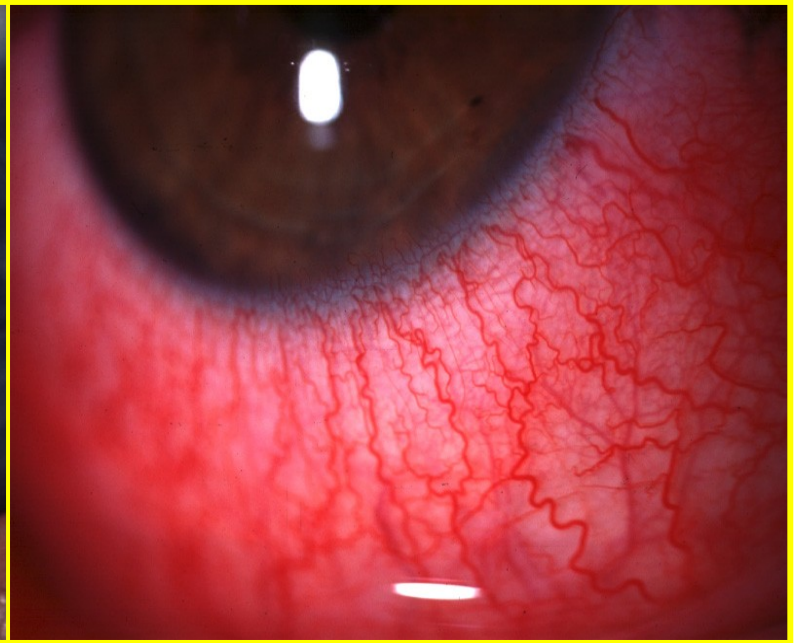

Simple diffuse episcleritis

Treatment

- Topical steroids
- Systemic ibuprofen (200 mg tid if unresponsive

Nodular episcleritis

- Less common than simple episcleritis
- May take longer to resolve
- Treatment - similar to simple episcleritis

Localized nodule which can be moved over sclera

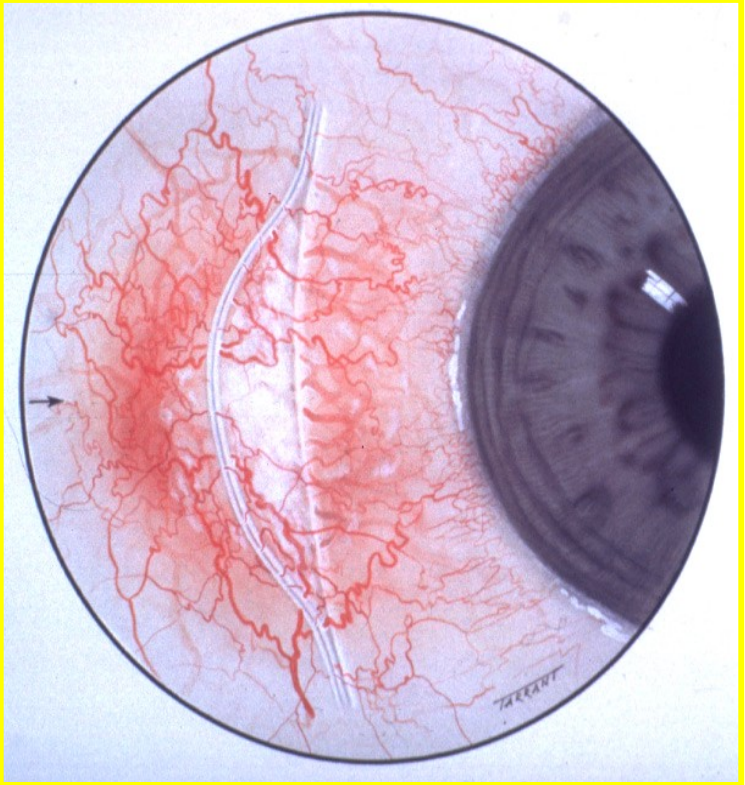

Deep scleral part of slit-beam not displaced

Causes and Systemic Associations of Scleritis

1. Rheumatoid arthritis

2. Connective tissue disorders

- Wegener granulomatosis
- Polyteritis nodosa
- Systemic lupus erythematosus

3. Miscellaneous

- Relapsing polychondritis
- Herpes zoster ophthalmicus
- Surgically induced

Diffuse anterior non-necrotizing scleritis

- Relatively benign - does not progress to necrosis
- Widespread scleral and episcleral injection

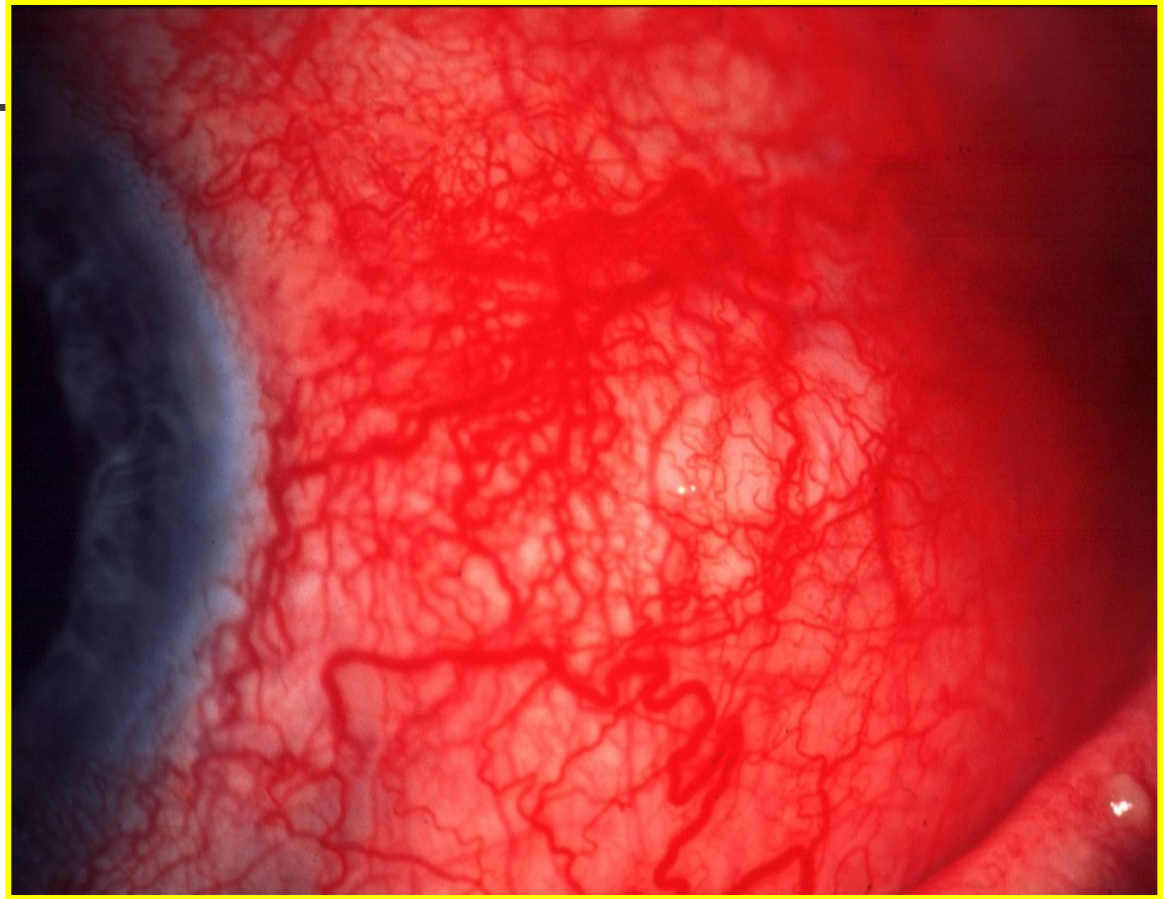

Treatment

- Oral NSAIDs
- Oral steroids if unresponsive

Nodular anterior non-necrotizing scleritis

More serious than diffuse scleritis

On cursory examination resembles nodular episcleritis

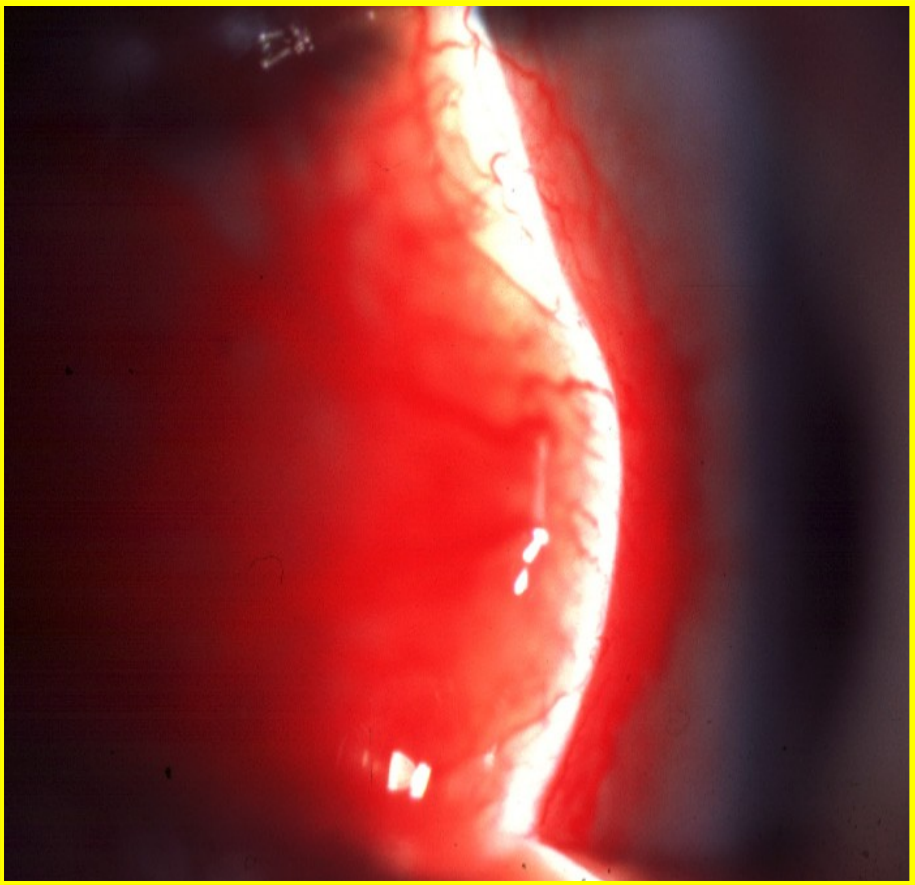

Scleral nodule cannot be moved over underlying tissue

Treatment - similar to diffuse non-necrotizing scleritis

Anterior necrotizing scleritis with inflammatio

- Painful and most severe type
- Complications - uveitis, keratitis, cataract and glaucoma

Progression

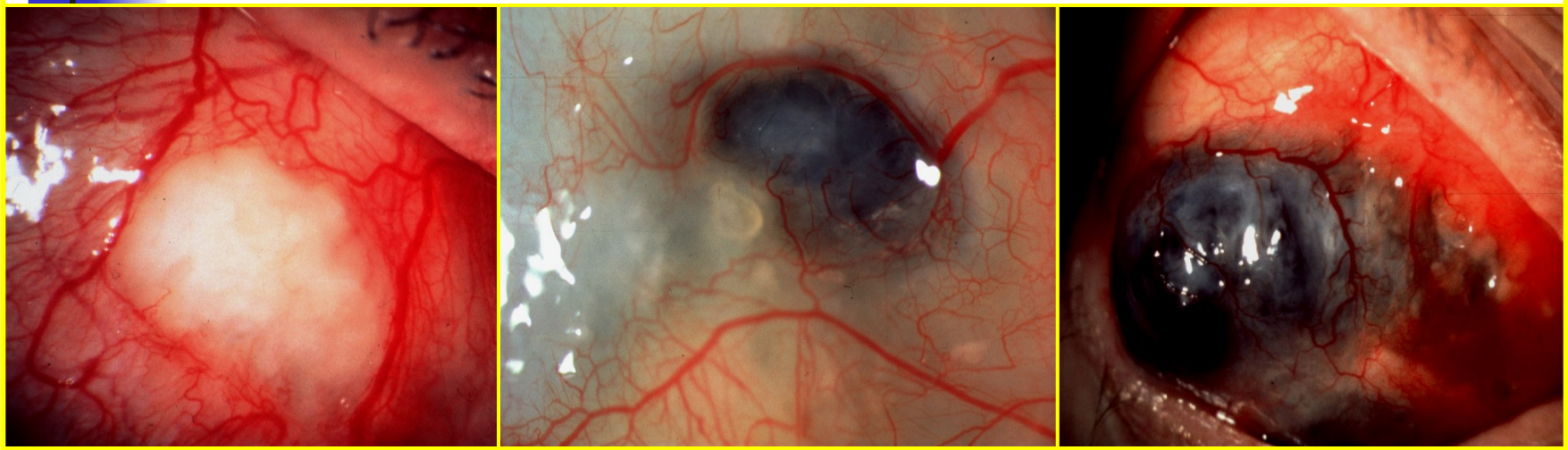

Avascular patches	Scleral necrosis and visibility of uvea	Spread and coalescence of necrosis

Treatment

- Oral steroids
- Immunosuppressive agents (cyclophosphamide, azathioprine, cyclosporin)
- Combined intravenous steroids and cyclophosphamide if unresponsive

Anterior necrotizing scleritis with inflammation (scleromalacia perforans)

- Associated with rheumatoid arthritis
- Asymptomatic and untreatable

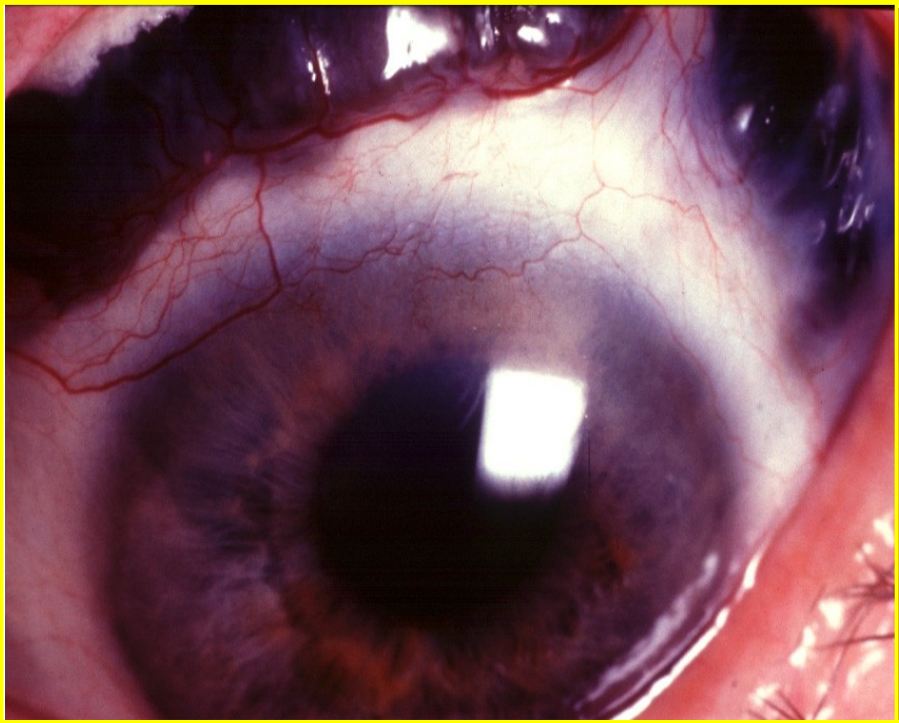

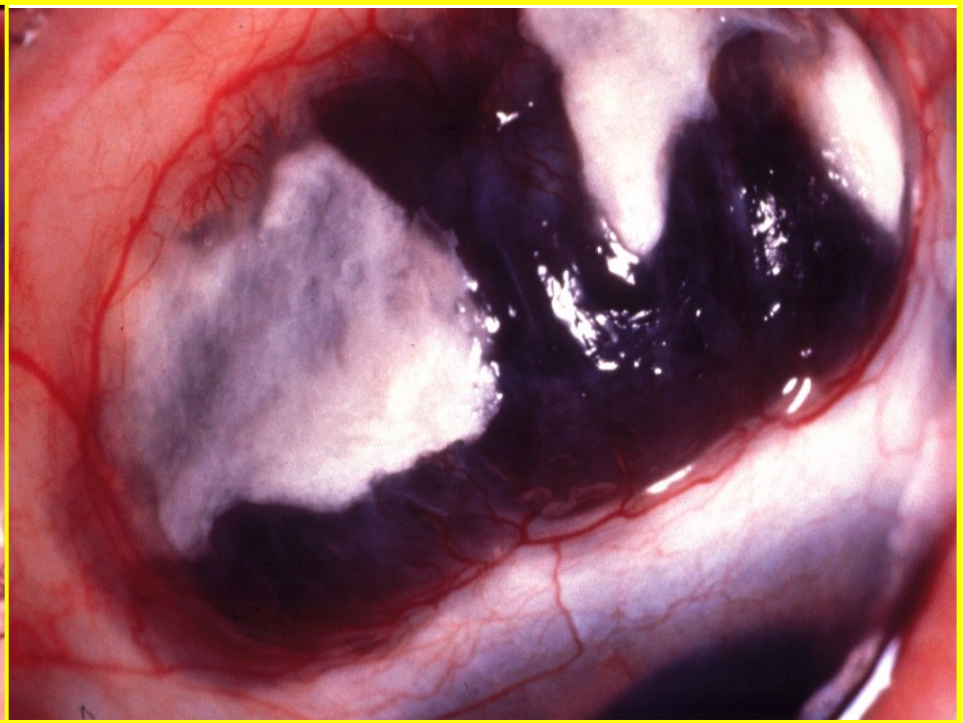

Progressive scleral thinning with exposure of underlying uvea

Posterior scleritis

- About 20% of all cases of scleritis
- About 30% of patients have systemic disease
- Treatment similar to necrotizing scleritis with inflammation

Signs

Proptosis and ophthalmoplegia

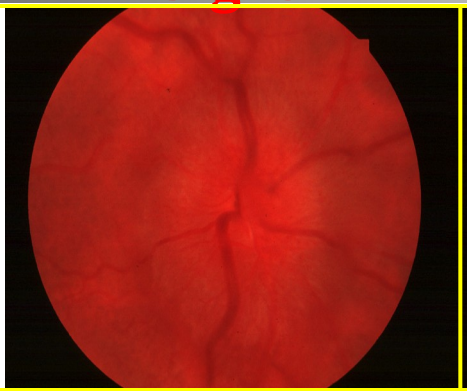

Disc swelling

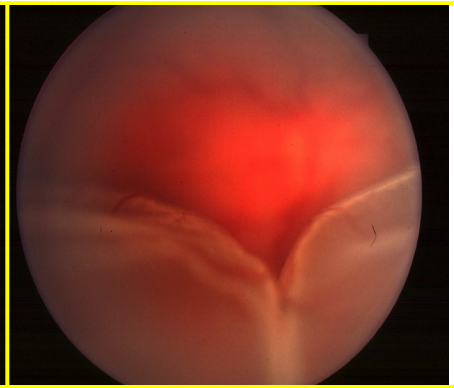

Exudative retinal detachment

Ring choroidal detachment

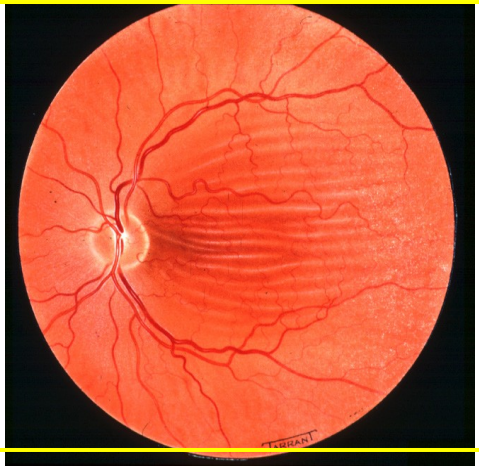

Choroidal folds

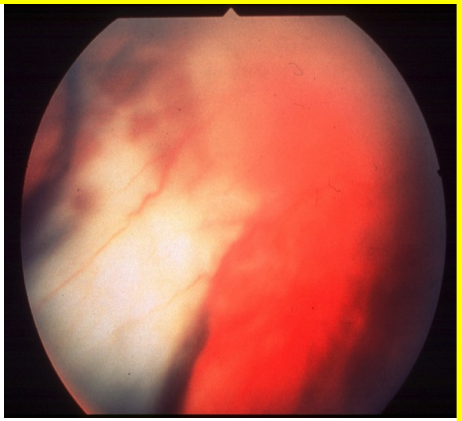

Subretinal exudation

Imaging in posterior scleritis

Ultrasound	Axial CT
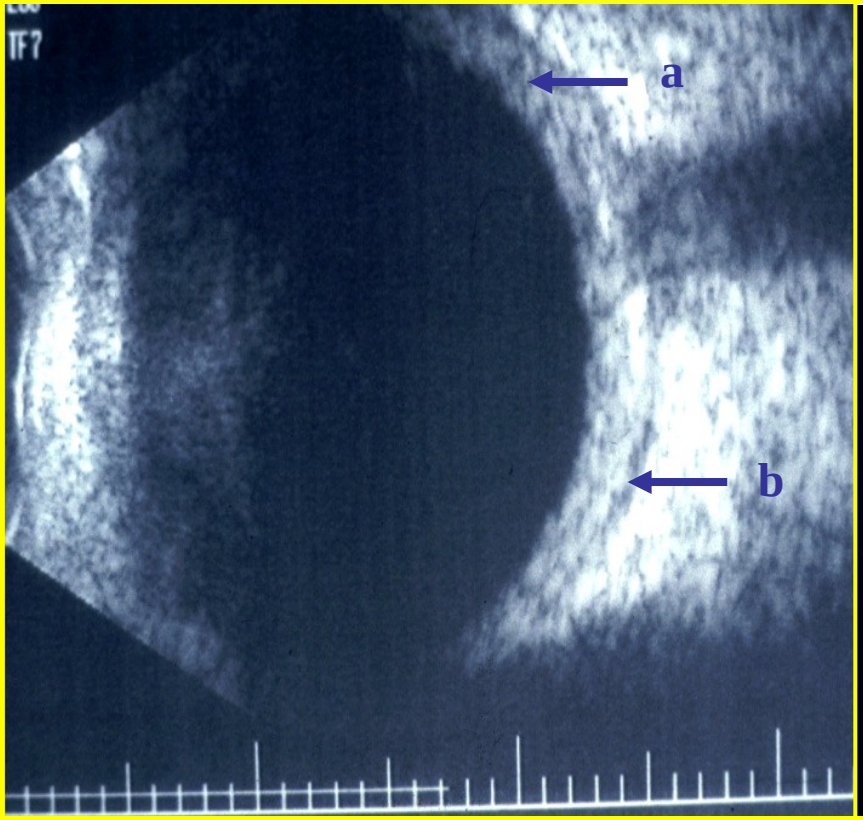	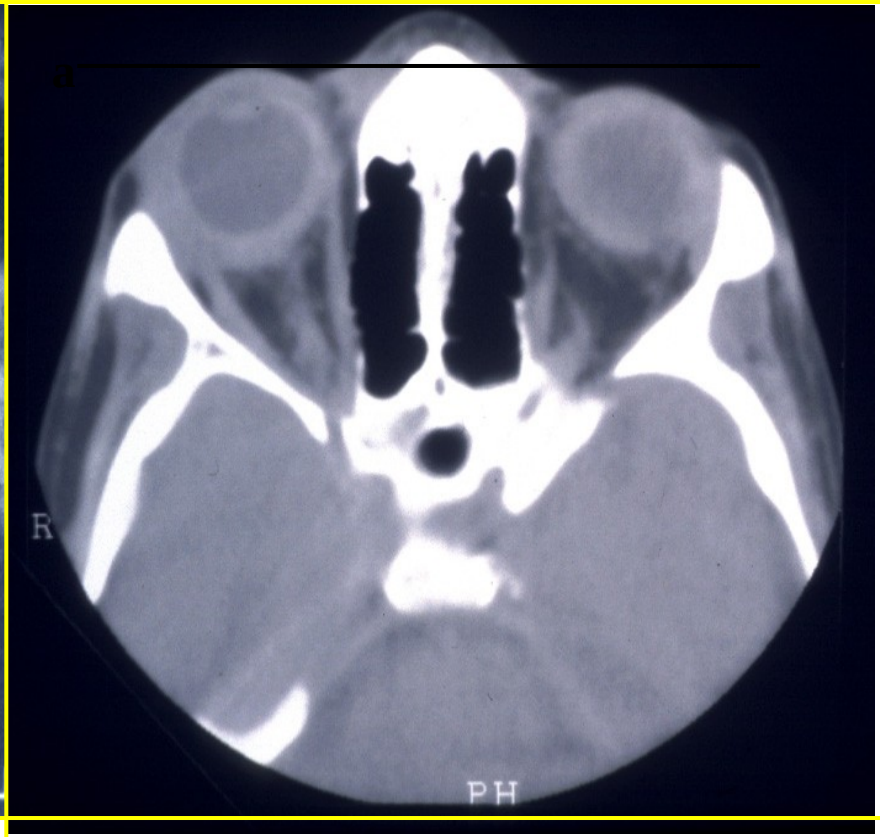
a - Thickening of posterior sclera b -Fluid in Tenon space (‘T’ sign)	Posterior scleral thickening

Acute angle-closure glaucoma

- An acute increase in IOP to several times the normal 10-21mmHg due to sudden blockage in drainage
- F>M
- Commonly Caucasian, Asian, Cushites. Rare in blacks.
- Presentation –dim lighting, emotions, sudden ocular pain, nausea & vomiting, headache, visual loss, haloes, repeated episodes

Anatomical predispositions

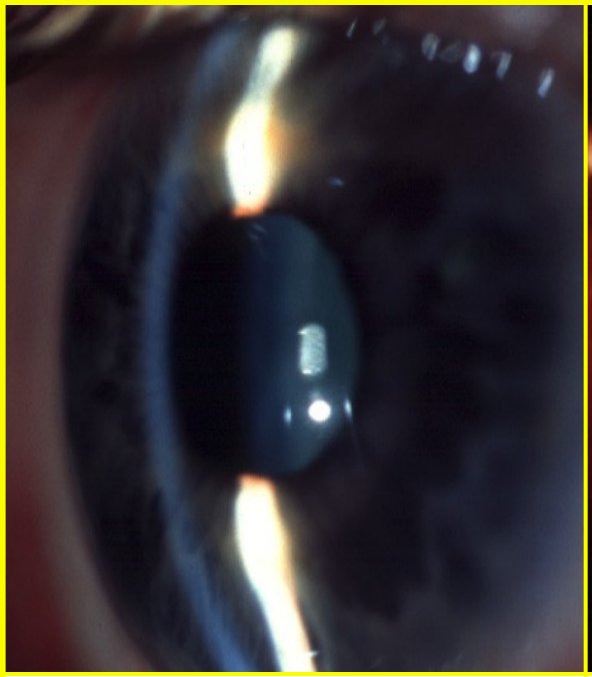

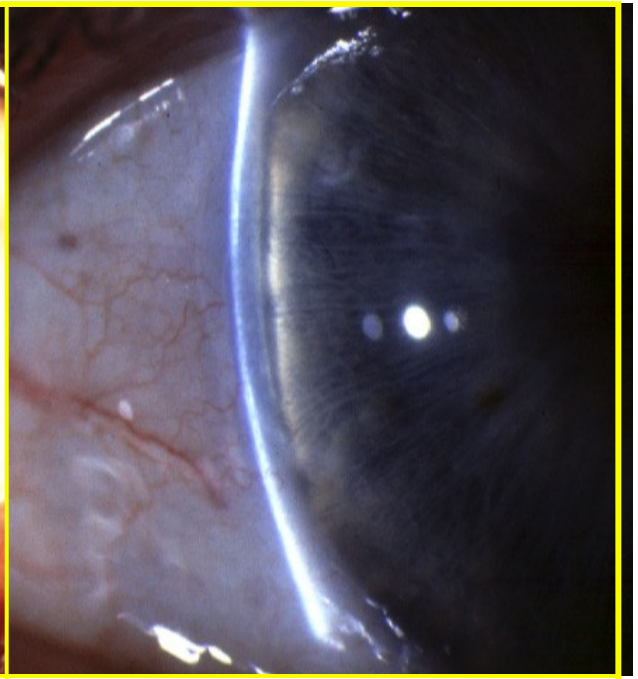

• Convex iris-lens diaphragm	• Shallow anterior chamber	• Narrow entrance to chamber angle

Pupil block

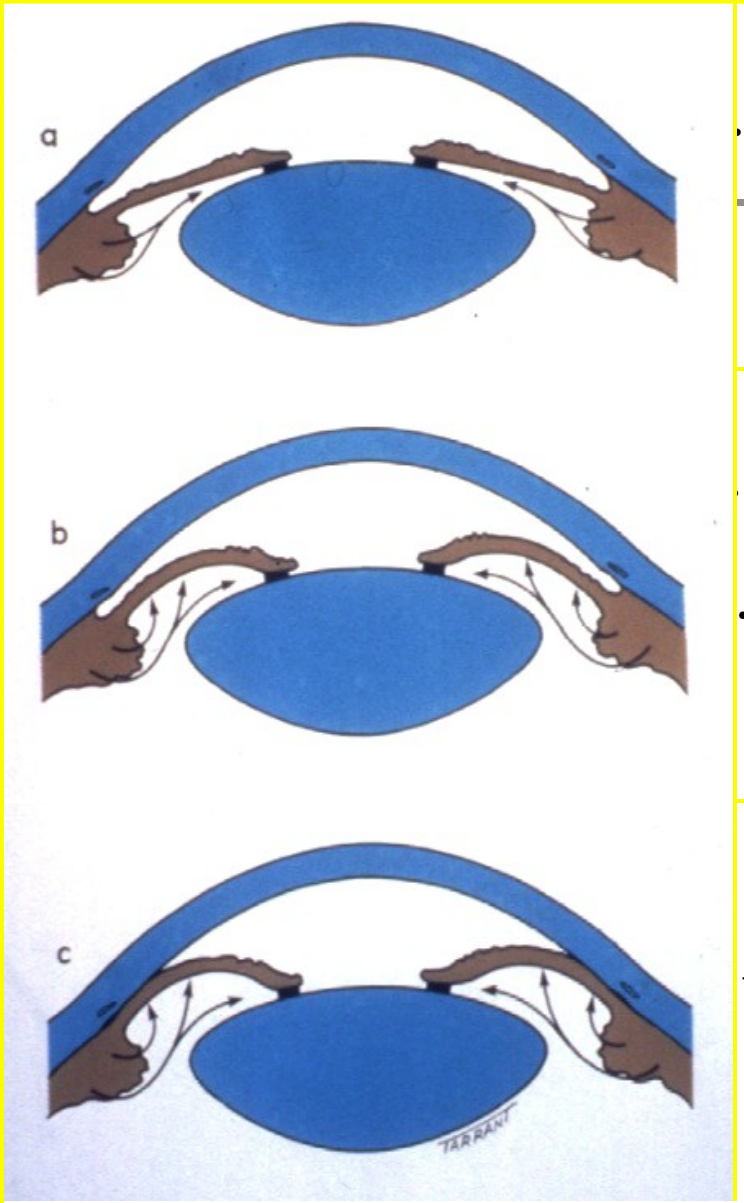

- Increase in physiological pupil block

- Dilatation of pupil renders peripheral iris more flaccid
- Increased pressure in posterior chamber causes iris bombé

Angle obstructed by peripheral iris and rise in IOP

Acute congestive angle-closure glaucoma

Signs

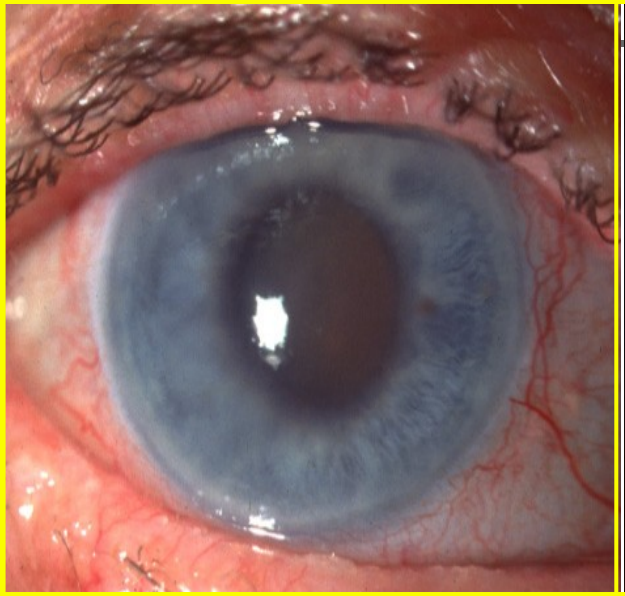

- Severe corneal oedema
- Dilated, unreactive, vertically oval pupil

- Ciliary injection
- Shallow anterior chamber

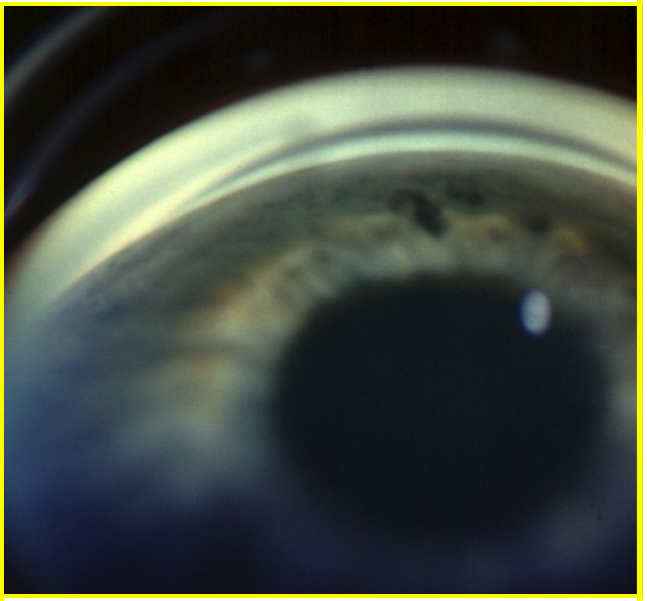

- Complete angle closure (Shaffer grade 0)

Treatment of Acute Congestive Angle-Closure Glaucoma

1. **Acetazolamide 500 mg i.v.**

2. **Hyperosmotic agents** - if appropriate
   - Oral glycerol 1-1.5 g/kg of 50% solution in lemon juice
   - Intravenous mannitol 2g/kg of 20% solution

3. **Topical therapy**
   - Pilocarpine 2% to both eyes
   - Beta-blockers
   - Steroids

4. **YAG laser iridotomy**
   - To both eyes when cornea is clear

Simple bacterial conjunctivitis

Signs

Crusted eyelids and conjunctival injection

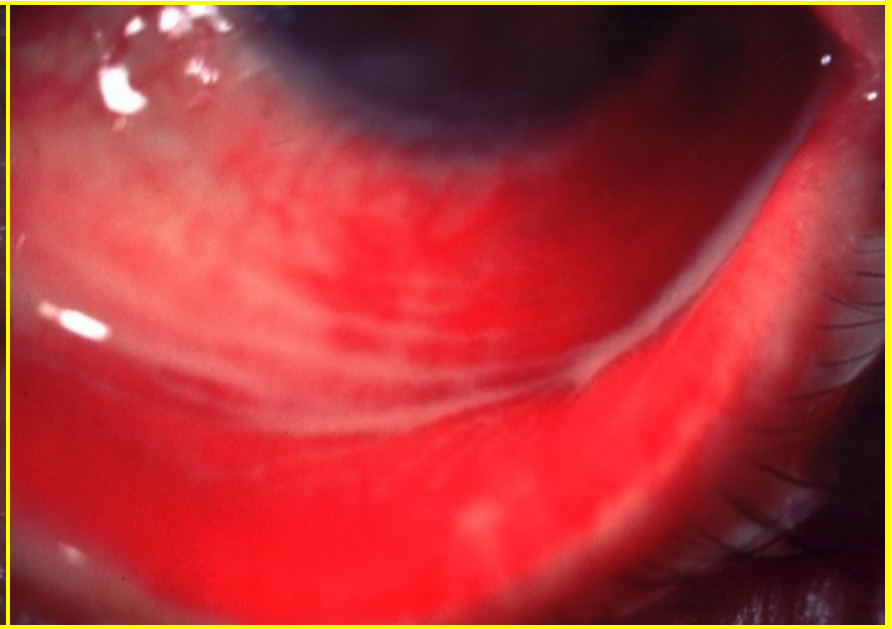

Subacute onset of mucopurulent discharge

Treatment - broad-spectrum topical antibiotics

Gonococcal keratoconjunctivitis

Signs	Complications
	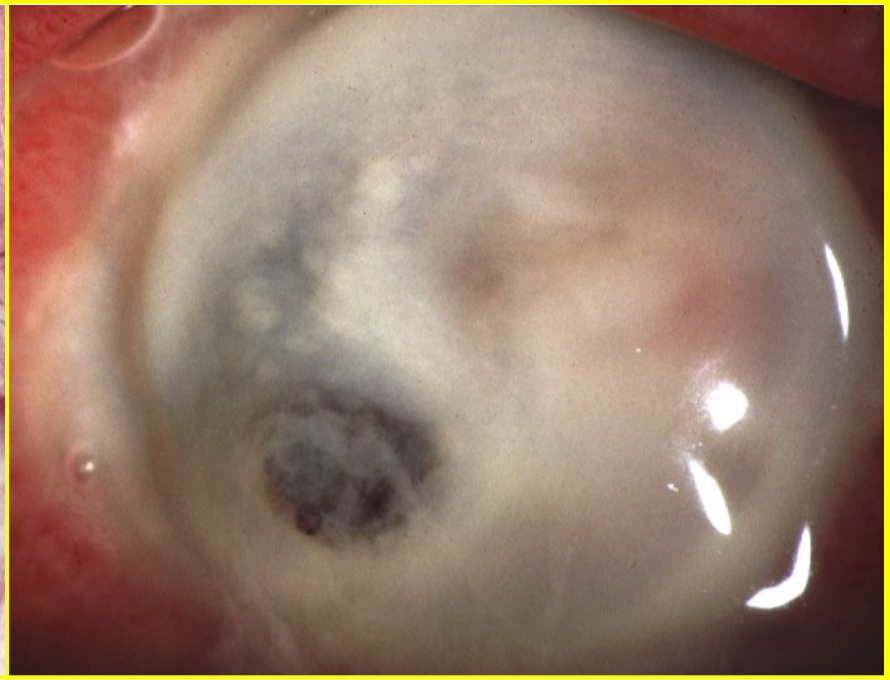
Acute, profuse, purulent discharge, hyperaemia and chemosis	Corneal ulceration, perforation and endophthalmitis if severe

Treatment

- Topical gentamicin and bacitracin
- Intravenous cefoxitin or cefotaxime

Pterygium

Seborrheic blepharitis

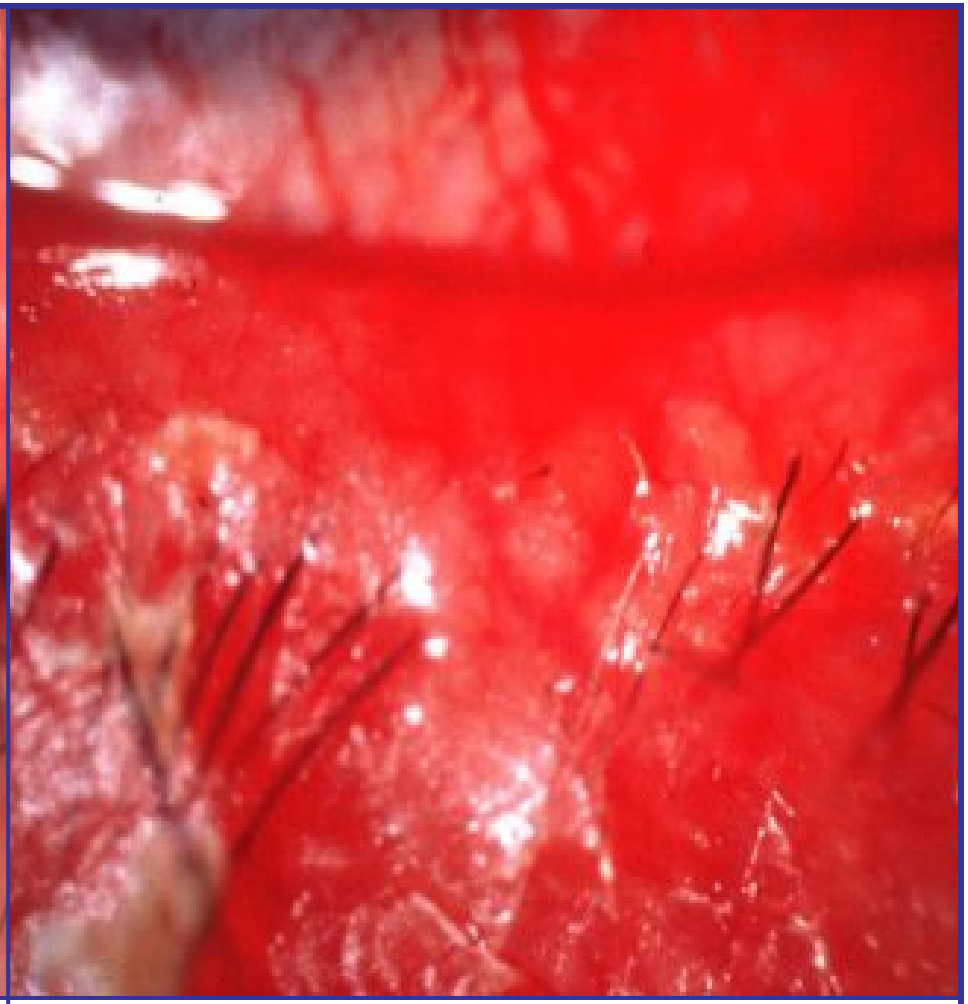

Chronic irritation worse in mornings

Scales around base of lashes (collarettes)

Hyperaemia and telangiectasia of anterior lid margin

Scarring and hypertrophy if longstanding

Complications of staphylococcal blepharitis

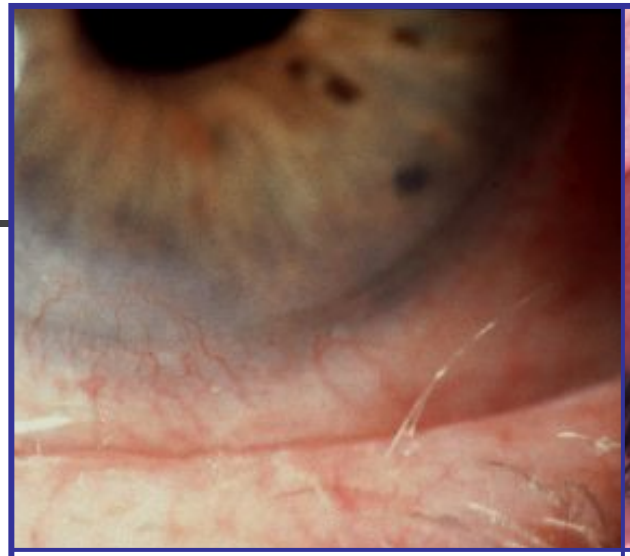

Trichiasis, poliosis

Recurrent styes

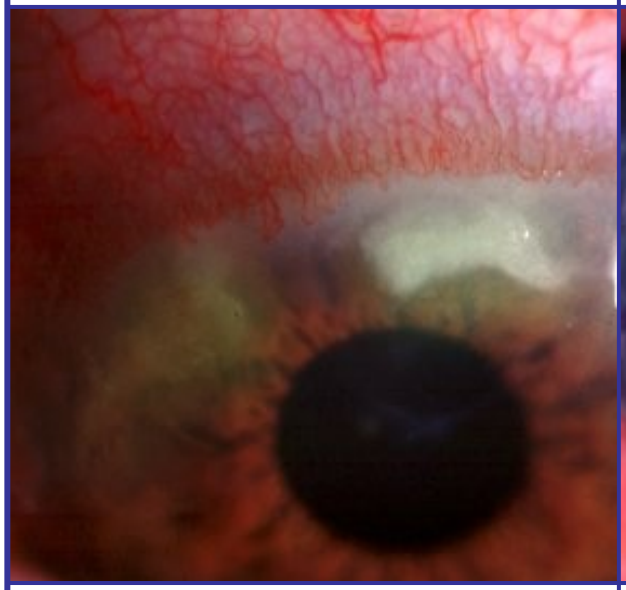

Marginal keratitis

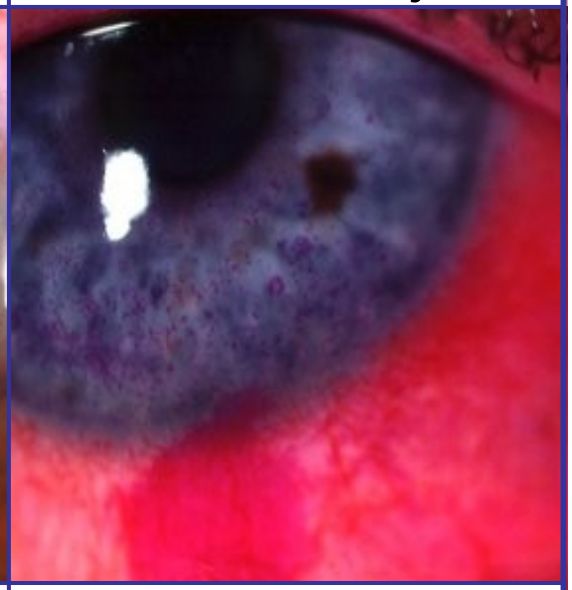

Tear film instability